CLINICAL ORTHOPAEDICS AND RELATED RESEARCH
Number 448, pp. 259–266
© 2006 Lippincott Williams & Wilkins

Orthopaedic • Radiology • Pathology Conference

Leg Pain and Swelling in a 22-Year-Old Man

Mustafa H. Khan, MD*; Ritesh Darji, MD†; Uma Rao, MD‡; and Richard McGough, MD*

HISTORY AND PHYSICAL EXAMINATION

The patient was a 22-year man who presented with right leg pain and swelling that had increased during the last 6 years. He complained of pain with walking and running, which precluded him from participating in any sports, and night pain. The patient localized the pain over the anterior aspect of the midtibia. He denied any history of trauma. He required regular doses of oxycodone for the past year to achieve adequate pain relief. His past medical history was unremarkable.

On physical examination a large anterior pretibial bony mass was palpable. No other masses were palpable in the extremities and there was no evidence of lymphadenopathy. Active and passive range of motion testing and neurovascular examination was in normal limits.

Plain radiographs and MRI scans of the leg, along with CT scan of the leg and chest, were obtained (Figs 1–3). Based on the history, physical examination and radiographic imaging, what is the differential diagnosis?

From the *Departments of Orthopedic Surgery, †Radiology, and ‡Pathology; University of Pittsburgh Medical Center, Pittsburgh, PA.
Each author certifies that he or she has no commercial associations (eg, consultancies, stock ownership, equity interest, patent/licensing arrangements, etc) that might pose a conflict of interest in connection with the submitted article.
Each author certifies that his or her institution has approved the reporting of this case report and that all investigations were conducted in conformity with ethical principles of research.
Correspondence to: Richard McGough, MD, Department of Orthopedic Surgery, 5200 Centre Avenue, Suite 415, Pittsburgh, PA 15232. Phone: 412-802-4100; Fax: 412-802-4120; E-mail: mcgoughrl@upmc.edu.
DOI: 10.1097/01.blo.0000195924.36103.11

Fig 1. (A) Anteroposterior and (B) lateral plain radiographs show a large multiseptated, expansile, cystic lesion in the tibial diaphysis. The anterior cortex appears thin with some periosteal reaction.

Fig 2. A sagittal CT scan shows the soap bubble appearance of the lesion. The tumor was less than 1 cm away from the distal tibial articular surface.

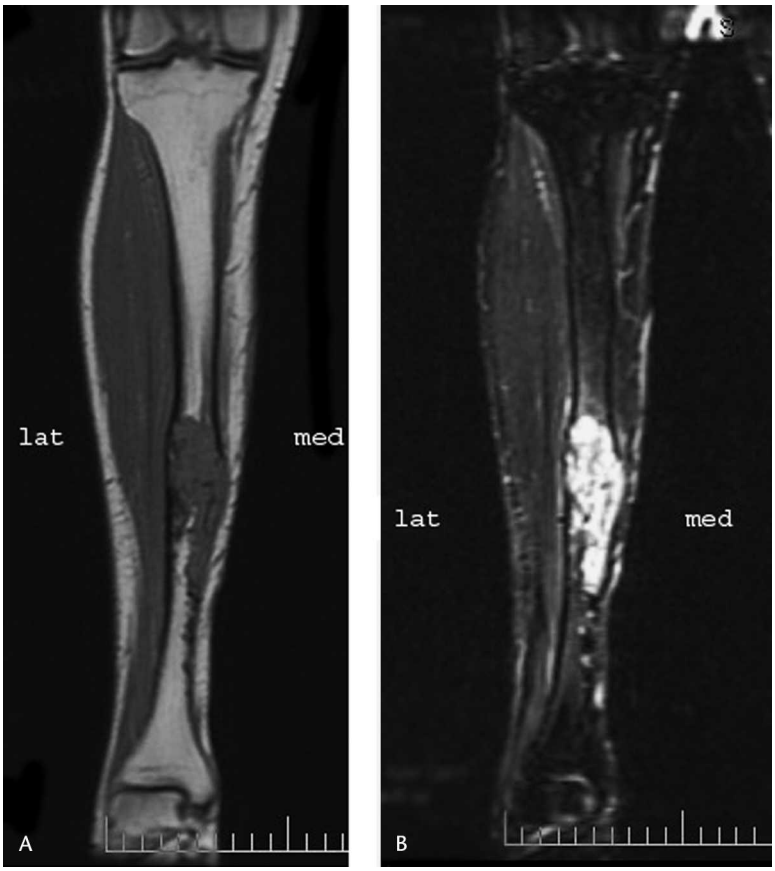

Fig 3A–B. (A) Coronal MRI T1 and (B) FSEIR images show that the mass was heterogeneous in nature.

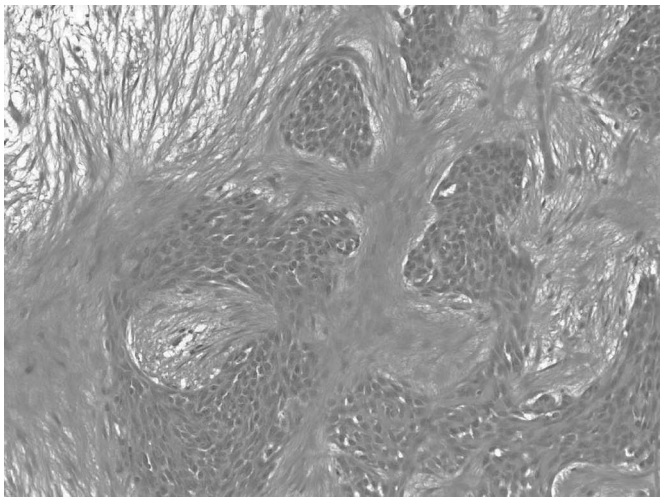

Fig 4. A pictomicrograph of a representative area of the tumor shows characteristic slightly basaloid nests of epithelial cells surrounded by spindle cells (Stain, hematoxylin and eosin; original magnification, ×20)

IMAGING INTERPRETATION

Plain radiographs showed a large predominantly lytic lesion with some internal sclerosis extending from the midtibial diaphysis to the distal tibia (Fig 1). The lesion was multiloculated and occupied the entire medullary cavity proximally where it expanded and thinned the cortex, particularly along the anteromedial aspect. More distally, it appeared to be predominantly cortically based and eccentric in location.

A CT scan was used to delineate the extent of the lesion (Fig 2). The lesion had a soap bubble appearance, and there was evidence of anterior cortical disruption. The tumor was located approximately 1 cm from the distal articular surface of the tibia. A chest CT scan did not show any thoracic metastases or lymphadenopathy.

Magnetic resonance imaging showed that the lesion was heterogeneous and multiloculated and predominantly isointense to muscle on T1 and hyperintense on T2 with persistently low signal of internal septae (Fig 3). There was some diffuse enhancement after gadolinium contrast administration. However, there was no soft-tissue component associated with the lesion. The tumor originated approximately 19 cm from the tibial plateau and extended to within 8 mm of the posterolateral tibial plafond without violation of the ankle joint. The posterior cortex was thinned but not breached.

DIFFERENTIAL DIAGNOSIS

Osteofibrous dysplasia (Campanacci's disease)
Adamantinoma
Fibrous dysplasia
Ewing's sarcoma/primitive neuroectodermal tumor

An incisional biopsy with frozen section was performed (Fig 4). Based on the history, physical examination, radiographic imaging and histology, what is the diagnosis and how should this lesion be treated?

See page 263 for diagnosis and treatment.

Continuation of ORP conference from page 262.

HISTOLOGY INTERPRETATION

On gross examination the biopsy specimen had a rubbery texture and was white-gray in color. Microscopic examination showed that it was a biphasic tumor composed of loosely arranged spindle cells in a storiform pattern mingled with clusters of epithelial cells (Fig 4). Osteoid with and without osteoblastic rimming was present in adjacent spindle cell stroma. Immunostains of the epithelial and spindle cells were strongly positive with pankeratin. No increased mitotic activity was noted.

DIAGNOSIS

Adamantinoma

DISCUSSION AND TREATMENT

Adamantinoma is a low-grade malignant bony neoplasm of unclear embryological origin that classically occurs in the tibia or fibula. The earliest descriptions of this tumor were by Maier[17] in 1900 and Fischer in 1913.[11] A review of 200 cases showed that the average age at presentation is in the early 30s, with a slight male predominance.[20] It is a rare entity, constituting less than 0.1 to 0.3% of all malignant tumors of the bone.[19,20,32] More than 80% of all adamantinomas occur in the tibial diaphysis, while the majority of the rest occur in the fibula, femur, ulna, and radius.[20,24] Though fibular involvement is often seen with adamantinomas, this was not the case with our patient. There are extremely rare reports of adamantinomas arising exclusively from the pretibial soft tissues without any bony involvement.[3,18] Interestingly, these soft tissue adamantinomas were histologically identical to their bony counterparts.

The initial symptoms of adamantinoma are often indolent and nonspecific. Most patients present with swelling that may or may not be accompanied by pain. Patients often tolerate these nonspecific symptoms for many years before seeking medical attention. Pathological fractures may be present in as many as 23% of patients.[24] There have been reports of hypercalcemia associated with adamantinomas.[1,33]

An association with trauma was first suggested by Ryrie in 1932, who believed that cellular hyperplasia leading to neoplasia after a traumatic event may be an important event in the development of the disease.[29] The association with trauma is often speculated upon in the literature but is of unknown significance. In a series of 200 patients, 61% had an antecedent history of trauma,[20] whereas another study of 32 patients reported a history of trauma in 25% of the affected individuals.[12] On the other hand, in a series of 85 patients only five patients recalled a traumatic event.[15] Though this issue has been brought up in the literature, there is no clear evidence to suggest causality.

The embryological origin of adamantinoma continues to be debated. Early reports suggested that the tumor derived from fetal crest,[11] basal cell lineage[29] and endothelial cells.[16,25] However, recent opinion seems to suggest that adamantinoma is a tumor of epithelial origin. Ultrastructural studies have shown that adamantinoma cells have epithelial characteristics such as a basal lamina, desmosomes, gap-junctions, epithelial-specific keratin and an extracellular composition similar to epithelial tissue.[10,21,22,26,27] Some authors have reported an association of adamantinomas with fibrous dysplasia.[8,35] Histologically, areas resembling fibrous dysplasia, consisting of fibroblasts in a storiform pattern, are frequently seen in adamantinomas.[35] Fibrous dysplasia, which is most frequently metaphyseal and/or diaphyseal in location, can be differentiated based on its characteristic well-circumscribed ground glass appearance on plain radiographs. Histologically, fibrous dysplasia is characterized by immature, woven bone that is unable to differentiate into mature lamellar bone; however, the presence of irregular trabeculae resembling Chinese letters is a characteristic of fibrous dysplasia. Adamantinomas have also been associated with osteofibrous dysplasia (Campanacci's disease).[23] The two lesions share strong clinical and histopathological similarity, with both having a tibial predominance.[4,14] Osteofibrous dysplasia, a benign tumor with aggressive behavior, is characteristically seen in the anterior cortex of tibia. Radiographically it is a lytic, multiloculated lesion that can cause anterior and/or posterior bowing. Its histological appearance is one of irregular spicules of bone lined by osteoblasts, which produce a rim of lamellar bone around areas of woven bone. Some authors have suggested that osteofibrous dysplasia and adamantinoma form a continuum of pathological processes where osteofibrous dysplasia-like adamantinoma is the intermediate step.[31] The final entity that needs to be considered in the differential diagnosis is Ewing's sarcoma, which is a highly malignant tumor that belongs to the primitive neuroectodermal tumor (PNET) family. It is most frequently found in the femur, tibia, and humerus, and its radiographic appearance is that of a lytic, centrally-located lesion that causes onion skin periosteal reaction. The microscopic appearance of Ewing's sarcoma is one of densely packed small blue cells with little cytoplasm packed in sheets. The disease has a characteristic t(11:22)(q24;q12) translocation, and has an aggressive, malignant biological behavior.[2] The radiographic and histological features of the tumor in this report were most consistent with a diagnosis of adamantinoma.

Plain radiographs are often diagnostic because of the tumor's classic location and appearance. More than 80% of all adamantinomas are found in the tibial diaphysis, and cortical and medullary involvement can occur. Some tumors may be confined to the cortex only. The tumor may break through the cortex and present with a soft tissue component. Metaphyseal involvement makes the diagnosis more challenging because other tumors have to be considered in the differential diagnosis. The typical radiographic appearance of the lesion is that of an expansile, eccentric mass with areas of bony destruction that may be accompanied by a variable amount of periosteal reaction. There may be cortical thinning, usually involving the anterior tibial cortex, and the mass may appear multiloculated with septations. For this reason, its appearance often is described as consisting of soap bubbles. Large-sized lesions may produce a deformity of the tibia, and concomitant involvement of the fibula can occur. Most adamantinomas are aligned along the proximal-distal axis in the bone. In less than 15% of the cases is there any soft tissue involvement. Magnetic resonance imaging and CT scans are helpful in delineating the extent of the tumor in the bony and soft tissues and may aid in surgical planning.

Flow cytometry studies have shown aneuploidy in the epithelial component of adamantinomas, suggesting that it may represent the primary malignant component.[13] Morphologically, the most common feature of this lesion is the presence of epithelial cells surrounded by spindle-cell stroma.[30] Though several histological subtypes of adamantinomas have been described, they have not correlated with biologic behavior. There are some reports that suggest a more aggressive behavior for basaloid and spindled variants.[7,18,35]

An open biopsy is usually required for definitive diagnosis, though a needle biopsy sometimes is sufficient. The tumor typically has an epithelial and a spindle cell component. The epithelial component may be basaloid, squamoid, or spindled. Cytological anaplasia and pleomorphism is unusual and mitoses are difficult to find. Areas resembling osteofibrous dysplasia may be present. Some tumors with complex tubular pattern may be mistaken for vascular neoplasms and those with epithelial or squamous areas can be mistaken for metastatic carcinoma. In cases where there is a predominance of spindle cells with scattered scant small epithelial nests, the tumor may be misdiagnosed as a synovial sarcoma. Therefore, radiological correlation, age, and other clinical features are essential for establishing a diagnosis of adamantinoma.

Adamantinomas are slow-growing tumors that can metastasize and may recur locally. Because of the propensity of the tumor for local spread and recurrence, early authorities were of the opinion that amputation of the affected extremity was curative and that it might improve survival.[5,6,9,28] However, subsequent studies have challenged

Fig 5A–D. (A) Gross appearance of the tumor resected en bloc is shown. (B) A contralateral vascularized osteocutaneous fibular autograft is shown before and (C) after inlay into tibial allograft. (D) The final appearance of the graft at the end of the procedure is shown.

Fig 6A–B. (A) Anteroposterior and (B) lateral plain radiographs taken 6 months postoperatively show the tibial allograft inlaid with contralateral fibular autograft secured with locking plates proximally and distally.

this view and have led to changes in treatment. Because of their slow-growing nature, surgical treatment has moved away from amputation. There are no prospective studies comparing amputation and limb-preserving surgery for the treatment of adamantinomas. The trend towards limb-preserving surgery is largely related to evolving and improving experience of surgeons with other tumors and patient preference for limb-preservation. Amputation for adamantinomas has not been shown to improve survival when compared with limb-preserving surgery but may be considered as a last resort if local recurrence occurs of if en-bloc resection and limb-salvage is not an option.[19] Therefore, limb salvage is currently the preferred method of treatment for adamantinomas. In a series of 32 patients, Hazelbag et al showed that curettage and excisional biopsy was associated with high rates of local recurrence and metastatic spread, whereas none of the patients treated with en-bloc resection had such complications.[12] Therefore, large segmental resection of the tumor followed by limb reconstruction has gained favor as the treatment of choice. Limb reconstruction can be performed with distraction osteogenesis, allografts, autografts (vascularized or nonvascularized) and metallic segmental replacement. Vascularized fibular autografts have been successfully used to reconstruct large segmental defects of long bones.[34] Reconstruction with tibial allograft is also an option.[20] However, tibial allograft reconstruction may be accompanied by high rates of nonunion (24%) and fracture (23%).[24] Radiation therapy and chemotherapy are of limited usefulness in the treatment of adamantinomas because the tumor is usually not very responsive to these modalities.[12,35] Chemotherapy may be considered in situations such as unresectable chest disease and radiation may be considered in cases with a microscopically positive margins. However, the utility of newer chemotherapeutic agents has not been fully studied in the treatment of adamantinomas.

Because of its rarity and the small numbers of patients in the available clinical series, the natural history of adamantinoma remains to be fully elucidated. There is data to suggest that the disease may have a more aggressive and lethal progression in young women[20] while other series have come to the opposite conclusion.[15] Rates of local recurrence vary from 18% to 32%,[12,15] while rates of metastasis are reported to be 15% to 30%.[12,15,20] Metastatic spread to lymph nodes is a late finding in the course of the disease. Mortality rates in the literature have varied from 13% to 18%.[15,20] In a review of 70 patients, en bloc tumor resection with wide margins and limb salvage was shown to have a 10-year survival rate of 87%.[24]

We had an extensive discussion with our patient about the risks and benefits of complex reconstruction versus amputation surgery. The patient chose to proceed with limb reconstruction surgery. Therefore, wide resection of the distal tibia, sparing the ankle joint itself, and composite reconstruction with tibial allograft inlaid with contralateral vascularized osteocutaneous fibular allograft was performed (Fig 5). The construct was secured with locked plates. The resected tibia was sent for pathology, which confirmed that the margins were tumor-free. Postoperatively, the patient was nonweightbearing. At the 6 month postoperative visit, the incisions had completely healed and the patient had no tenderness to palpation along the tibia. Radiographs showed excellent alignment of the bone graft with early signs of bony healing at the proximal and distal osteosynthesis sites (Fig 6).

References

1. Altmannsberger M, Poppe H, Schauer A. An unusual case of adamantinoma of long bones. *J Cancer Res Clin Oncol*. 1982;104:315–320.
2. Aymore IL, Meohas W, Brito de Almeida AL, Proebstner D. Case report: periosteal Ewing's sarcoma: case report and literature review. *Clin Orthop Relat Res*. 2005;434:265–272.
3. Bambirra EA, Nogueira AM, Miranda D. Adamantinoma of the soft tissue of the leg (letter to the editor). *Arch Pathol Lab Med*. 1983; 107:500–501.
4. Benassi MS, Campanacci L, Gamberi G, Ferrari C, Picci P, Sangiorgi L, Campanacci M. Cytokeratin expression and distribution in adamantinoma of the long bones and osteofibrous dysplasia of tibia and fibula: an immunohistochemical study correlated to histogenesis. *Histopathology*. 1994;25:71–76.
5. Braidwood AS, McDougall A. Adamantinoma of the tibia: report of two cases. *J Bone Joint Surg Br*. 1974;56:735–738.
6. Bullough PG, Goldberg VM. Multicentric origin of adamantinoma of the tibia: a case report. *Rev Hosp Spec Surg*. 1971;1:71–73.
7. Campanacci M, Giunti A, Bertoni F, Laus M, Gitelis S. Adamantinoma of the long bones: the experience at the Istituto Orthopedico Rizzoli. *Am J Surg Pathol*. 1981;5:533–542.
8. Cohen DM, Dahlin DC, Pugh DG. Fibrous dysplasia associated with adamantinoma of the long bones. *Cancer*. 1962;15:515–521.
9. Dunne RE. Primary adamantinoma of the tibia. *N Engl J Med*. 1938;218:634–637.
10. Eisenstein W, Pitcock JA. Adamantinoma of the tibia: an eccrine carcinoma. *Arch Pathol Lab Med*. 1984;108:246–250.
11. Fischer B. Uber ein primaries adamantinom der tibia. *Frankfurt Z Path*. 1913;12:422.
12. Hazelbag HM, Fleuren GJ, Cornelisse CJ, Van den Broek LJ, Taminiau AH, Hogendoorn PC. DNA aberrations in the epithelial cell component of adamantinoma of long bones. *Am J Pathol*. 1995; 147:1770–1779.
13. Hazelbag HM, Taminiau AH, Fleuren GJ, Hogendoorn PC. Adamantinoma of the long bones: a clinicopathological study of thirty-two patients with emphasis on histological subtype, precursor lesion, and biological behavior. *J Bone Joint Surg Am*. 1994;76:1482–1499.
14. Ishida T, Iijima T, Kikuchi F, Kitagawa T, Tanida T, Imamura T, Machinami R. A clinicopathological and immunohistochemical study of osteofibrous dysplasia, differentiated adamantinoma and adamantinoma of long bones. *Skeletal Radiology*. 1992;21:493–502.
15. Keeney GL, Unni KK, Beabout JW, Pritchard DJ. Adamantinoma of long bones: a clinicopathologic study of 85 cases. *Cancer*. 1989; 64:730–737.
16. Llombart-Bosch A, Ortuno-Pacheco G. Ultrastructural findings supporting the angioblastic nature of the so-called adamantinoma of the tibia. *Histopathology*. 1978;2:189–200.
17. Maier C. Ein primaries myelogenes Plattenepithel-carcinom der Ulna. *Bruns' Beitr Klin Chir*. 1900;26:553.
18. Mills SE, Rosai J. Adamantinoma of the pretibial soft tissue: clinicopathological features, differential diagnosis and possible relationship to intraosseous disease. *Am J Clin Pathol*. 1985;83:108–114.
19. Mirra JM. Adamantinoma and fibrous dysplasia. In: JM Mirra, ed. *Bone Tumors: Clinical, Radiologic and Pathologic Correlations.* Philadelphia, PA: Lea and Febiger; 1989:1204–1231.
20. Moon NF, Mori H. Adamantinoma of the appendicular skeleton: updated. *Clin Orthop Relat Res*. 1986;204:215–237.
21. Mori H, Yamamoto S, Hiramatsu H, Yoshida A, Fukunishi R. Adamantinoma of the tibia: ultrastructural and immunohistochemical study with reference to histogenesis. *Clin Orthop Relat Res*. 1984; 190:299–310.
22. Perez-Atayde AR, Kozakewich HP, Vawter GF. Adamantinoma of the tibia: an ultrastructural and immunohistochemical study. *Cancer*. 1985;55:1015–1023.
23. Putnam A, Yandow S, Coffin CM. Classic adamantinoma with osteo-fibrous dysplasia-like foci and secondary aneurismal bone cyst. *Pediatr Dev Pathol*. 2003;6:173–178.
24. Qureshi AA, Shott S, Mallin BA, Gitelis S. Current trends in the management of adamantinoma of long bone: an international study. *J Bone Joint Surg Am*. 2000;82:1122–1131.
25. Reed RJ. Malignant myxoid angioblastoma of bone. *Am J Surg Pathol*. 1982;6:159–163.
26. Rosai J. Adamantinoma of the tibia: electron microscopic evidence of its epithelial origin. *Am J Clin Pathol*. 1969;51:786–792.
27. Rosai J, Pinkus GS. Immunohistochemical demonstration of epithelial differentiation in adamantinoma of the tibia. *Am J Surg Pathol*. 1982;6:427–434.
28. Rosen RS, Schwinn CP. Adamantinoma of limb bone: malignant angioblastoma. *Am J Roent Radium Ther Nucl Med*. 1966;97:727–732.
29. Ryrie BJ. Adamantinoma of the tibia: aetiology and pathogenesis. *Br Med J*. 1932;2:1000.
30. Schajowicz F, Ackerman LV, Sissons HA. *Histological Typing of Bone Tumors. International Histological Classification of Tumors.* No 6. Geneva, Switzerland: World Health Organization; 1972.
31. Springfield DS, Rosenberg AE, Mankin HJ, Mindell ER. Relationship between osteofibrous dysplasia and adamantinoma. *Clin Orthop Relat Res.* 1994;309:234–244.
32. Unni KK, Dahlin DC, Beabout JW, Ivins JC. Adamantinomas of long bones. *Cancer.* 1974;34:1796–1805.
33. Van Schoor JX, Vallaeys JH, Joos GF, Roels HJ, Pauwels RA, Van der Straeten ME. Adamantinoma of the tibia with pulmonary metastases and hypercalcemia. *Chest.* 1991;100:279–281.
34. Weiland AJ, Moore JR, Daniel RK. Vascularized bone autografts: experience with 41 cases. *Clin Orthop Relat Res.* 1983;174:87–95.
35. Weiss SW, Dorfman HD. Adamantinoma of long bone: an analysis of nine new cases with emphasis on metastasizing lesions and fibrous dysplasia-like changes. *Hum Pathol.* 1977;8:141–153.